In Vivo MR Computation of Whole Proximal Femur Mechanical Competence Using Micro-Finite Element Analysis Applied to High-Resolution 3T MRI of Proximal Femur Microarchitecture

Alexandra Hotca[1,2], Chamith S. Rajapakse, PhD[3], Henry Rusinek, PhD[4], Stephen Honig, MD[5], Ryan Brown, PhD[6], Cem M. Deniz, PhD[6], Ravinder R. Regatte, PhD[6], and Gregory Chang, MD[1]

[1]Department of Radiology, NYU Langone Medical Center, Center for Musculoskeletal Care, New York, NY, United States, [2]Department of Biological Sciences, CUNY-Hunter College, New York, NY, United States, [3]Department of Radiology, University of Pennsylvania School of Medicine, Philadelphia, PA, United States, [4]Department of Radiology, New York University School of Medicine, New York, NY, United States, [5]Osteoporosis Center, Hospital for Joint Diseases, NYU Langone Medical Center, New York, NY, United States, [6]Department of Radiology, NYU Langone Medical Center, Center for Biomedical Imaging, New York, NY, United States

Introduction: The goal of this study was to apply micro-finite element analysis (μFEA) to high-resolution 3T magnetic resonance (MR) images of proximal femur microarchitecture to quantitatively assess the mechanical competence (stiffness) of the whole proximal femur *in vivo*. Osteoporosis is a disease of weak bone predisposing an individual to fracture. Fracture of the hip or proximal femur has the most devastating consequences, resulting in chronic pain, disability, and a mortality rate as high as 20% in the first year after fracture [1]. Currently, bone mineral density (BMD) is used to assess skeletal fragility and fracture risk. Bone microarchitecture is also a critical determinant of bone strength [2]. However, magnetic resonance imaging (MRI) and quantitative assessment of proximal femur microarchitecture *in vivo* can be challenging due to limitations in signal-to-noise (SNR) ratio for deeper anatomy, such as the hip. Only two groups have reported *in vivo* MRI of proximal femur microarchitecture [3, 4].

Materials and Methods: This study had institutional review board approval with written informed consent obtained from all subjects. The non-dominant proximal femur of four subjects with osteoporotic fractures (3 females, 1 male, mean age = 53.5 ± 18 years) and four controls without fracture (3 females, 1 male, mean age = 64 ± 4.7 years) were scanned on a 3T MRI scanner (Siemens Skyra, Erlangen, Germany) using a 26 element receive coil setup (18 elements from a flexible array coil anteriorly and 8 elements from a spine coil posteriorly) and a 3-D fast low-angle shot sequence (TR/TE = 37 ms/4.9 ms, 60 coronal images, matrix = 512 x 512, field of view = 120 mm, slice thickness = 1.5 mm, acquisition time = 29 minutes 30 seconds) [3]. Under the guidance of a musculoskeletal radiologist, the whole proximal femur was segmented for each subject. We applied micro-finite element analysis in the linear elastic regime for the whole proximal femur volumes of interest [5]. In brief, each voxel in the BVF map was converted into a hexahedral finite element with dimensions corresponding to the voxel size. Assuming empirically determined isotropic tissue modulus of 15 GPa and Poisson's ratio of 0.3 for bone, Young's modulus (YM) of each element was set to be linearly proportional to the BVF value such that YM in GPa is 15 x BVF for all elements. Simulated compression was applied along the bone's longitudinal axis by applying a constant displacement (1% strain) to all finite element nodes in the proximal face of the finite element mesh while keeping those in the distal face constrained. The FE system was solved to yield a 3D strain map for the whole bone section. Finally, the axial stiffness was obtained as the quotient of the applied strain on the proximal face and the resulting stress. Each subject also underwent assessment of total hip bone mineral density (BMD) T-scores via dual-energy x-ray absorptiometry (DXA, Hologic, Waltham, MA, USA). DXA is the standard-of-care imaging test for osteoporosis diagnosis. We performed the non-parametric Mann-Whitney test to assess differences in whole proximal femur stiffness and total hip BMD T-scores between groups.

Results: Individual trabeculae composing bone microarchitecture of the proximal femur were well visualized on images (Figure 1). A strain map (Figure 2) reveals spatial variation in strain within different regions of the proximal femur, with high strain in the femoral neck for loading in the standing position. Whole proximal femur stiffness was significantly lower ($p = 0.021$) in fracture cases (19.4 ± 6.2 kN/mm) compared to controls (40.2 ± 18.4 kN/mm). Differences in total hip BMD T-scores between fracture cases (-2.1 ± 1.1) and controls (-2.6 ± 0.07) were not significant ($p = 0.36$).

Discussion/Conclusion: Micro-finite element analysis applied to high-resolution 3T MRI of proximal femur microarchitecture can be used to detect reduced whole proximal femur stiffness in subjects with osteoporotic fractures compared to controls without fracture who do not differ by bone mineral density. If validated in a larger patient cohort, this technique might be used as an additional clinical tool to diagnose individuals with skeletal fragility at risk for fracture.

References: 1) Leibson et al. J Am Geriatr Soc. 2002;50:1644-50. 2) Dempster DW. Osteoporos Int. 2003;14(Suppl 5):S54-6. 3) Krug et al. Osteoporos Int. 2005;16:1307-14. 4) Chang et al. J Magn Reson Imaging DOI: 10.1002/jmri.24345. 5) Rajapakse et al. Radiology. 2012;262:921-931.

Figure 1. High-resolution 3T MRI of proximal femur microarchitecture in a control subject without fracture (left) and an osteoporotic subject with a history of fracture (right). Individual trabeculae are visible, and there is microarchitectural deterioration in the osteoporotic subject.
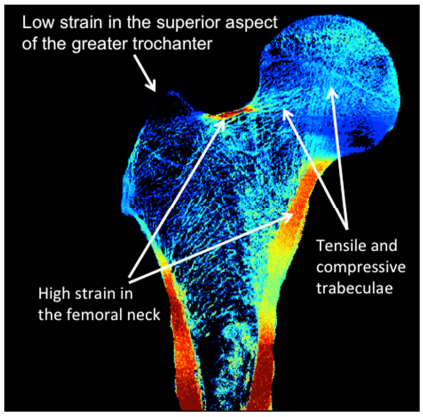
Figure 2. Strain map reveals spatial variation in strain in different regions of the femoral neck with loading in the standing position.